

“Thyroid Cytopathology”

Present Status and Future Directions


Syed Z. Ali, MD, FRCPath, FIAC
Professor of Pathology and Radiology
The Johns Hopkins Hospital, Baltimore, Maryland
USA



The 2010 Bethesda System for Reporting Thyroid Cytopathology

- Nondiagnostic or Unsatisfactory*
- Benign
- Atypia of Undetermined Significance (AUS) or FLUS*
- Suspicious for a Follicular Neoplasm or FN*
- Suspicious for Malignancy
- Malignant

Probabilistic Approach and Clinical Algorithms



Thyroid FNA – Impressive Present

- Global Impact Of TBSRTC And Other Reporting Terminologies
- Clinical Management Algorithms Redefined
- Powerful Introduction And Significant Influence Of Diagnostic Molecular Tests

TBSRTC

- 722,000 results on Google
- 158,000 citations on Google Scholar
- 2,362 articles on PubMed (unique)



Over 35k copies/e-books sold

TBSRTC 2017

Over 24.5k copies/e-books sold


TBSRTC (2010)

- New Data (Prospective Studies)
- Molecular Tests
- New ATA Guidelines (2015)
- NIFTP



TBSRTC (2017)

TBSRTC Probabilistic Approach and Clinical Algorithms



	ROM (%)	Management
•Nondiagnostic	(1-4) 5-10	Repeat FNA with US
•Benign	(0-3)	Follow-up
•AUS/FLUS	(10-15) 10-30	Repeat FNA, moleo testing or lobectomy
•SFN/FN	(15-30) 25-40	Moleo testing, lobectomy
•SFM	(60-75) 50-75	Near-total thyroidectomy or lobectomy
•Malignant	(97-99)	Near-total thyroidectomy or lobectomy*

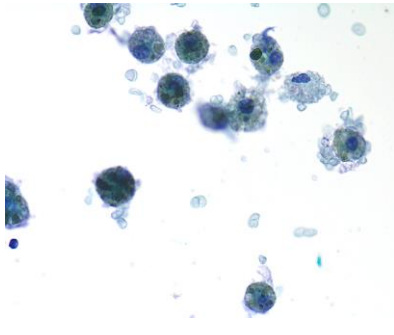
ATA 2016, Recommendation 8B*
For patients with thyroid cancer >1 cm and <4 cm without extra thyroidal extension, and without clinical evidence of any lymph node metastases (cNO), the initial surgical procedure can be either a bilateral procedure (near-total or total thyroidectomy) or a unilateral procedure (lobectomy). Thyroid lobectomy alone may be sufficient initial treatment for low-risk papillary and follicular carcinomas; however, the treatment team may choose total thyroidectomy to enable RA therapy or to enhance follow-up based upon disease features and/or patient preferences.

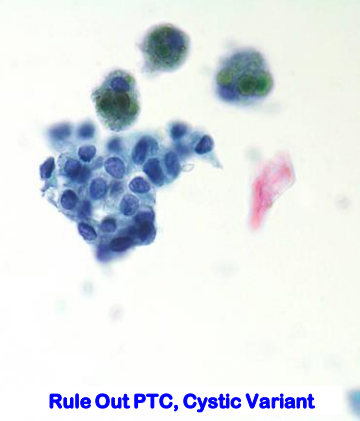
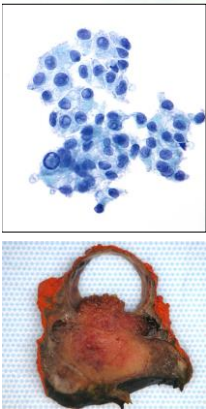
Nondiagnostic

ROM 5-10%

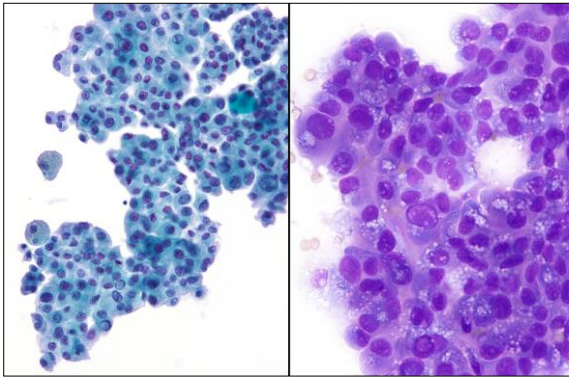
- Incidence: 2-20% (<10%)
- Adequacy criterion
 - At least 6 groups, each with at least 10 benign-appearing, well-visualized follicular cells (LBP - Same adequacy criteria)
 - Relaxing the adequacy criterion
 - fewer repeat FNAs
 - ~ 95% of ND are benign
 - < 3% FN Rate
- Exceptions
 - Chronic lymphocytic thyroiditis
 - Abundant colloid
 - Atypia or above
- Reaspirate at 3mo with U/S
 - New recommendation - Repeat at shorter interval

Cyst Fluid Only

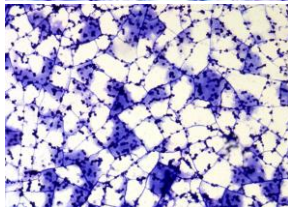
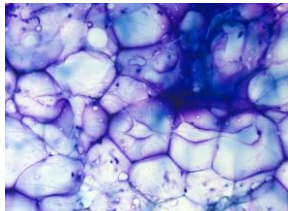
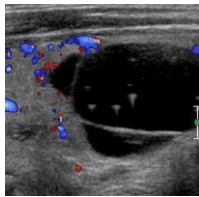




Rule Out PTC, Cystic Variant

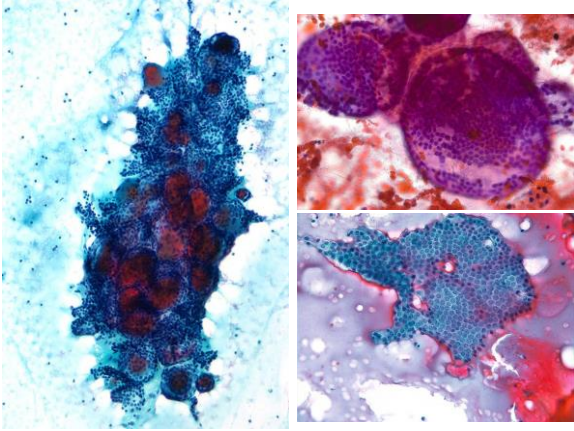


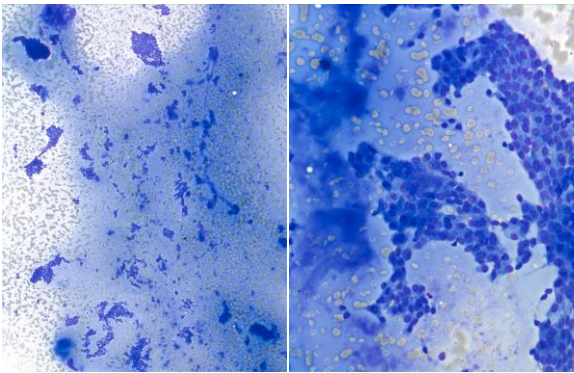
"Hypervacuolization"

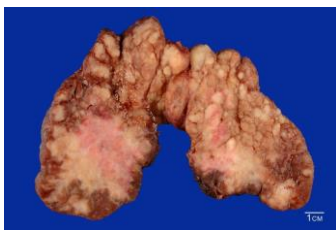
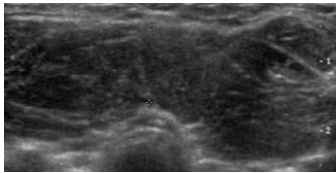


Benign
ROM 0-3%

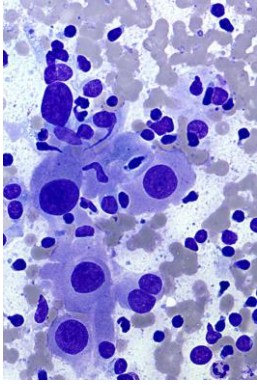
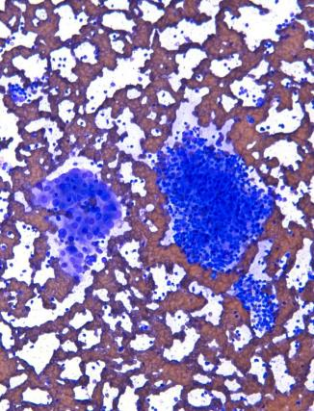
- **Included entities**
 - **Hyperplastic / Adenomatoid nodule**
 - **Colloid nodule**
 - **Chronic lymphocytic thyroiditis**
 - **Graves' Disease**
- **F/U by clinical and possibly US examination**

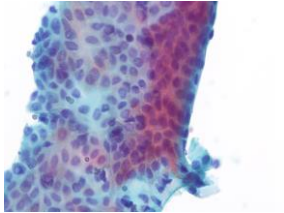
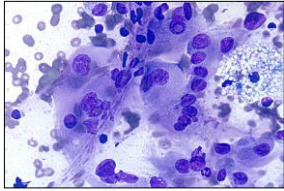
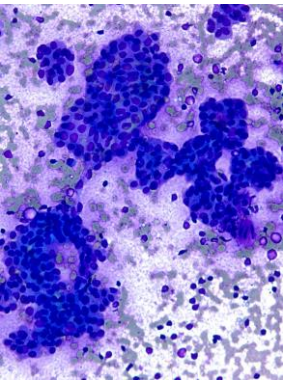


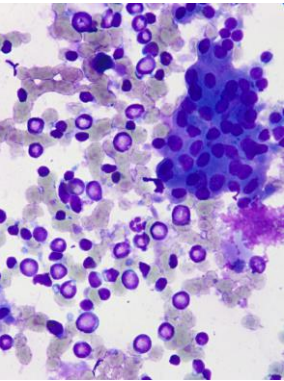
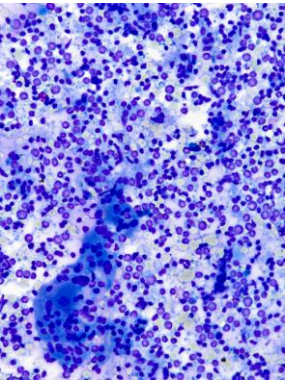




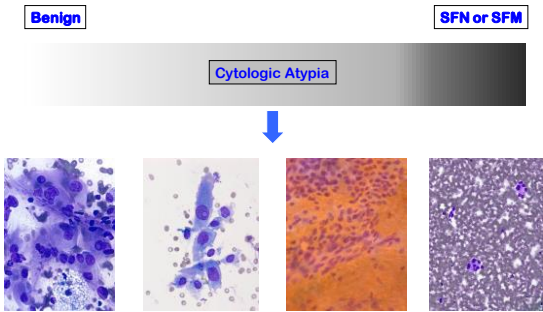
**Significant Cause
for a False
Positive FNA
Diagnosis**







AUS*/FLUS



AUS/FLUS

ROM 10-30%

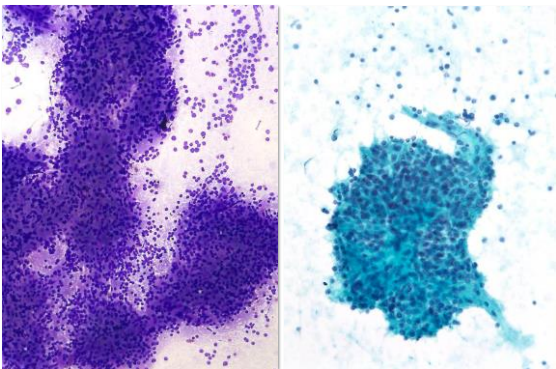
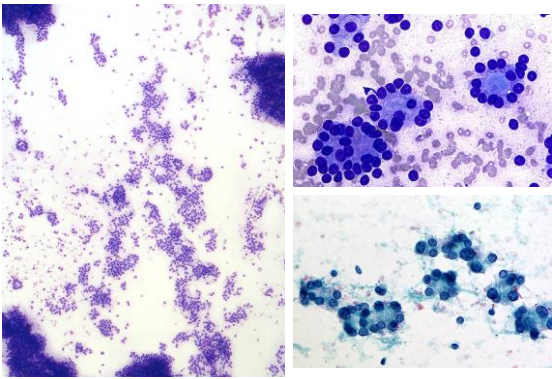
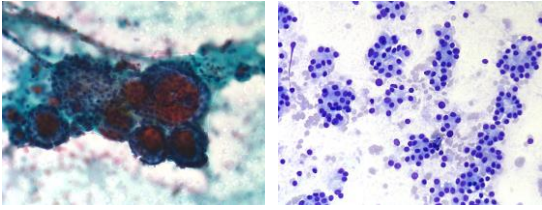
- **2017 – new subcategorization (descriptive)**
 - Cytologic atypia
 - Architectural atypia
 - Cytologic and architectural atypia
 - Hurthle cell AUS/FLUS
 - Atypia, NOS
- **A single diagnosis carries a low risk**
- **Avoid overuse of this category (new benchmark 10%)**
- **Impact of molecular tests**

Suspicious for a Follicular Neoplasm or Follicular Neoplasm

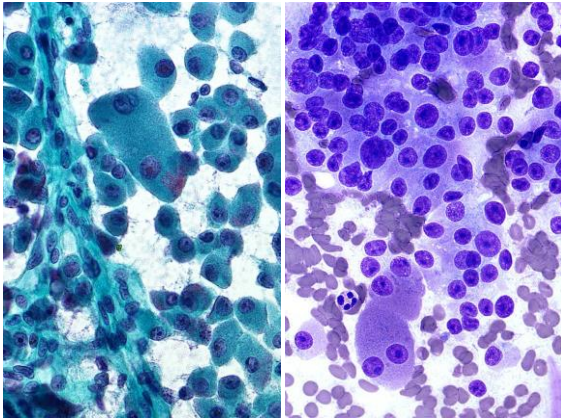
ROM 25-40%

- **Significant architectural atypia -**
 - a predominance of microfollicles and/or trabecula
 - **2017 - slight modification of the criteria (due to NIFTP)**
 - follicular patterned lesions with mild nuclear changes are included (but NOT INClc or papillae)
 - optional note- cannot r/o NIFTP
- **Distinction between follicular adenoma and CA**
- **Surgery (usually lobectomy) is needed for definitive diagnosis**

Macrofollicles Vs. Microfollicles



Needle washout for PTH



Hurthle Cell CA - A Different Disease?

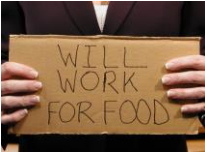- **Clinical**
 - Older
 - More advanced clinical stage
 - Invasion
 - Lymphatics → Cervical Nodes (Hematogenous → Lungs, liver, bone, typically after a longer latent period)
- **Molecular Profile**
 - TP53, PTEN
 - Infrequent RAS, PAX8-PPAR γ

Diagnostic Molecular Tests

- Increase pre-operative diagnostic accuracy
- FNA specimens excellent source for molecular testing
- **Very expensive** → linked to TBSRTC categories (AUS/FN)
- FNA + Molecular Tests (work in tandem)

FNA Dx → Molecular Test

Molecular Test → Reduces Diagnostic Surgeries



The “Rule Out” Test (High NPV)

Afirma® Gene Expression Classifier – GEC (Veracyte)

- Quantified mRNA expression of 167 genes – multidimensional algorithm (for Benign Vs Suspicious)
- Six specialized mRNA expression cassettes (MTC, PT, RCC, Bst CA, Melanoma)
- Problems with Hurthle cell classification
- Results – Benign (53%), Suspicious (38%), Indeterminate
- NPV-94%, PPV-38%



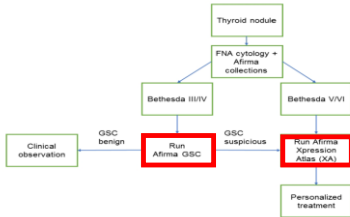
Afirma® Genomic Sequencing Classifier - GSC

- More comprehensive whole RNA transcriptome sequencing platform
- NPV-98%, PPV-47%
- Significant improvement in Hurthle cell classification

Afirma® Xpression Atlas - XA

- RNA-sequencing-based test
- Analyzes 511 genes associated with thyroid CA (BRAF, NTRK, EGFR, RET, ROS1, ALK, PAX8/PPARG, HRAS)

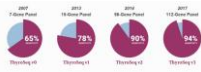Management Algorithm Integration of FNA and Molecular Testing



The “Rule In + Rule Out” Test (High NPV and PPV)

ThyroSeq® Genomic Classifier (V 3.0) UPMC and CBL Path

- Next generation DNA and RNA sequencing panel
- MTC and PT markers included
- NPV-98%, PPV-83%



The “Rule In + Rule Out” Test

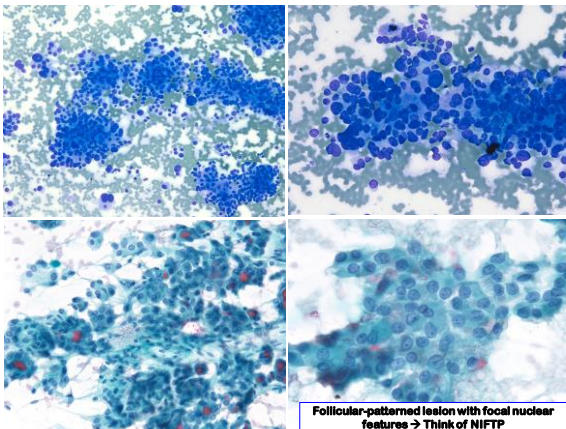
- **ThyGeNEXT® and ThyraMIR™**
 - ThyGenX – NGS mutational panel (10 genes, TERT, ALK)
 - ThyraMIR – miRNA GEC (10 miRNAs)
 - Performed in combination (ThyGenX neg → ThyraMIR)
 - Can be performed on stained FNA smears/LBP
 - **NPV-94%, PPV-74%**



Suspicious for Malignancy

PPV 65-75%

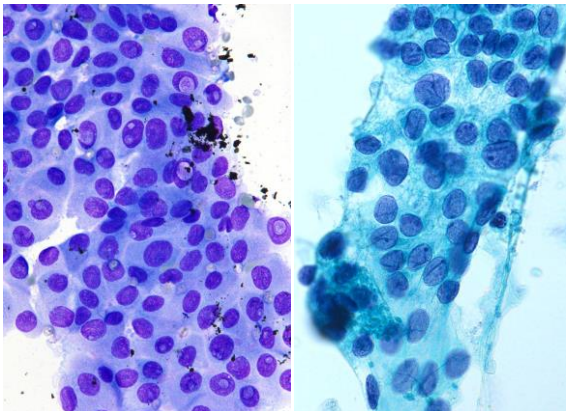
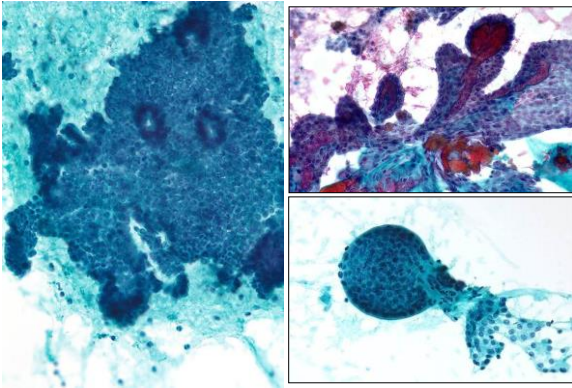
- **Suspicious for Papillary Carcinoma**
 - **2017 – some cases may need an optional note (FVPTC/NIFTP) → suggesting lobectomy**
- **Suspicious for Medullary Carcinoma**
- **Suspicious for Malignant Lymphoma**
- **Suspicious for Metastatic Cancer**

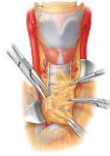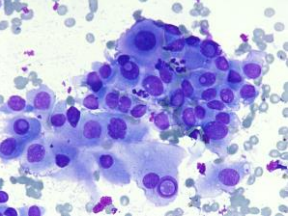
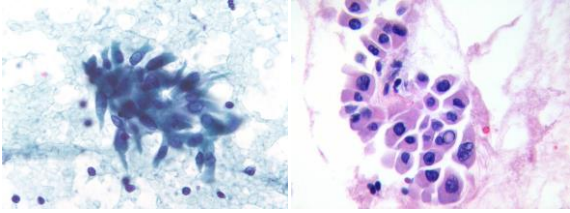


Malignant

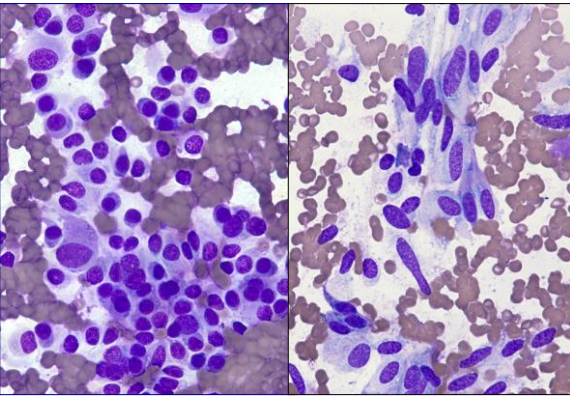
PPV 97-99%

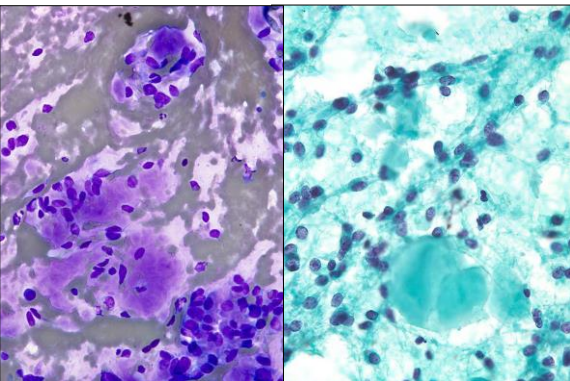
- Papillary carcinoma
 - Variants
 - 2017 – (to avoid FPs due to NIFTP) some modification of the definition and criteria (only cases with classical features – true papillae, PBs, INCIs)
 - optional note (for all PTC cases), 3-4% → NIFTP
- Medullary carcinoma
- Poorly differentiated carcinoma
- Anaplastic carcinoma
- Lymphoma
- Metastatic cancers
- Other

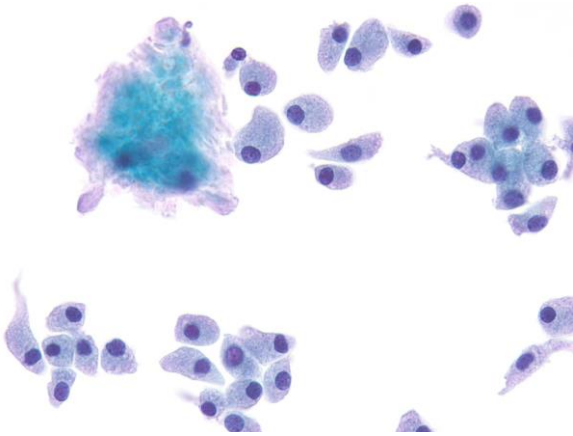


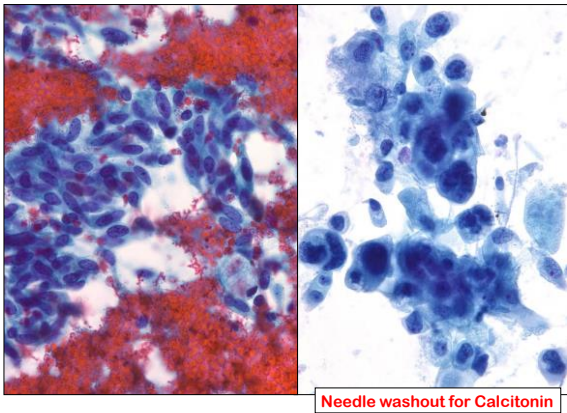


BRAF Testing

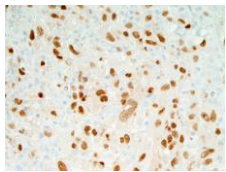
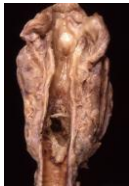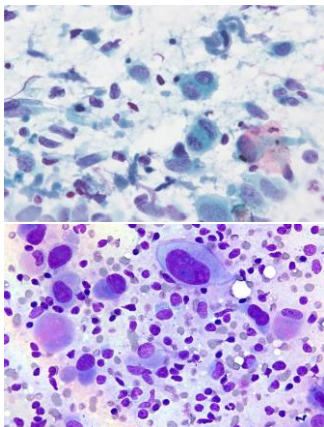






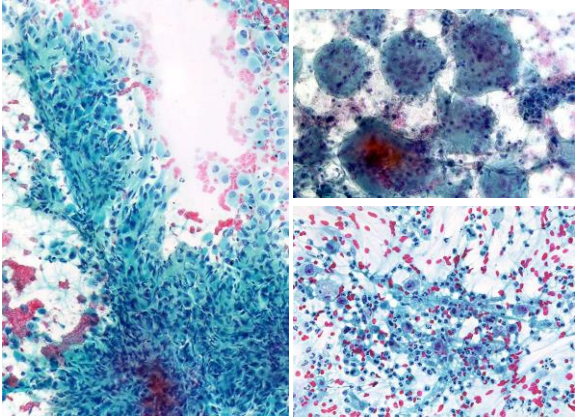


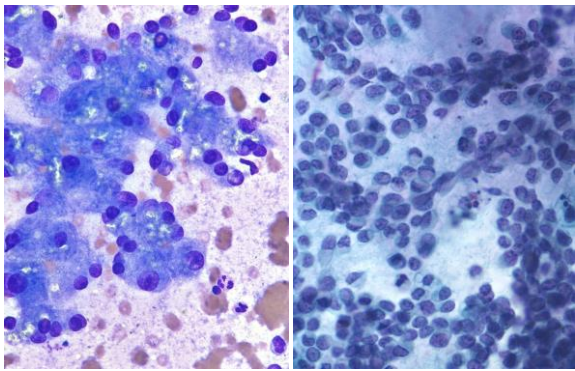
Needle washout for Calcitonin



PAX8 Positivity 76-79%

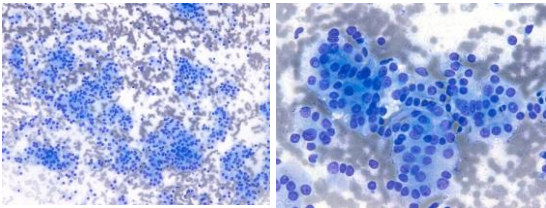
(Courtesy - Dr. J Bishop)





NIFTP

(Non-invasive Follicular Thyroid Neoplasm with Papillary-like Nuclear Features)



Cytopathologic diagnostic criteria for NIFTP? **NONE**

Should we be diagnosing NIFTP on FNA? **NO**

➤ NIFTP is a Histopathologic Diagnosis

Noninvasive, Encapsulated Follicular Variant Of Papillary Thyroid Carcinoma

Non-invasive Follicular Thyroid Neoplasm with Papillary-like Nuclear Features

- Educate your clinicians
- Good communication is needed
- Cyto-histo correlation could be crucial
- ❖ Cytopathology plays a screening role

➤ De-escalation of treatment (lobectomy)

Thyroid FNA Promising Future

- Molecular Tests for Cancer prognostics and Precision Medicine
- Machine Learning and CAD

Beyond The Primary Diagnosis Personalized Therapy

- Emerging evidence of correlation between genomic variants and tumor histology, behavior, predicted clinical course and therapeutic option
- **Dabrafenib plus trametinib*** for BRAF V600E mutated Anaplastic Thyroid Cancer
- **Larotrectinib*** for refractory solid tumors harboring a neurotrophic receptor tyrosine kinase (NTRK) gene fusion (regardless of cancer type)

*FDA approved

TERT and ALK Mutations

ThyGeNEXT

- Higher
 - Mortality
 - Incidence of LN mets
 - Post-treatment recurrence
 - Clinical stage
 - Incidence of extra-thyroidal extension
 - Vascular invasion
 - Potential for treatment failure

Machine Learning in Thyroid Imaging

- **Echo Texture Analysis** (echogenic appearance of the nodule - Benign vs Malignant) → CADs (Computer-aided Diagnostic) Systems
 - Homogeneous, heterogeneous, solid, cystic, complex, hypoechoic, isoechoic, mixed or hyperechoic
 - CAD → more objective –eliminating observer bias → standardize reporting → **better define ROM** → **avoid unnecessary FNAs**
- Extended to CT and MRI (cross sectional) and PET
- New Concept- **“Imaging Biopsy”**
- **Is it going to replace FNA?** (in few cases)

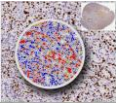
Applying Deep Learning to Thyroid Cytopathology

- **Extremely challenging**
 - Cytology has color
 - Too many variables (cellularity, type of stain, staining intensity, large number of slides, thickness of smears, etc.)
 - Cytology is 3-D (Z-stacks)
 - Too many cytologic and architectural patterns
- **What are we trying to achieve?**
 - Replacing pathologist/CT onsite presence?
 - Higher diagnostic accuracy?
 - Decreasing TAT?
 - Cost saving?

Applying Deep Learning to Cytopathology

Potential Uses

- Increased diagnostic accuracy and probability prediction
 - Certain geographic (remote) locations in the world
 - Lack of trained Cyto staff
- Reading IHCs (Cell proliferation, Triple stains, etc)



How would AI look like in future?

- Likely an "AI Chip" installed/built in the microscopes
- Self contained system? "The AI Box"
- Network-based/Cloud Deep Artificial Neural Networks
 - Pre-trained Convolutional Neural Network (CNN)
